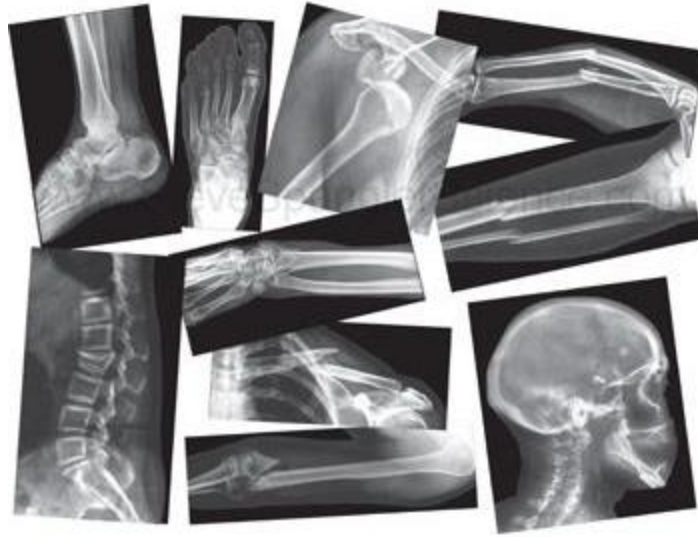

HARRIS ORTHOPAEDICS AND SPORTS MEDICINE

Bone Fracture



Introduction

All fractures must be taken seriously. If you think that a bone has been fractured and had not already seen immediate medical attention, do so immediately.

Anatomy

The Human skeletal system is made up of 206 bones and provides support, allows for movement, and protects the internal organs of the body.

Injury

Fractures, broken bones, cracks, hairline--you can call it what you wish, it means the same thing—fractures are among the most common orthopedic problems. Despite what you may have heard, a broken bone is not worse than a fracture; they both mean the same thing. A fractured bone is the same as a broken bone. In fact, the word fracture, according to the Oxford English Dictionary is defined as "the act of being broken." There are different types of fractures and broken bones, but these words mean the same thing!

Injury continue...

What Is a Fracture?

Most fractures happen because of a single and sudden injury (too much pressure is applied to a bone) however, there is a type of fracture that is caused over time (chronic) called a stress fracture (page 11). The diagnosis of a fracture is usually made with an x-ray film, but other types of test can be done to see if there is a fracture (see “Diagnosis” page 3 for more information). Fractures are commonly caused by a fall, strike from an object, or by twisting or bending of the bone.

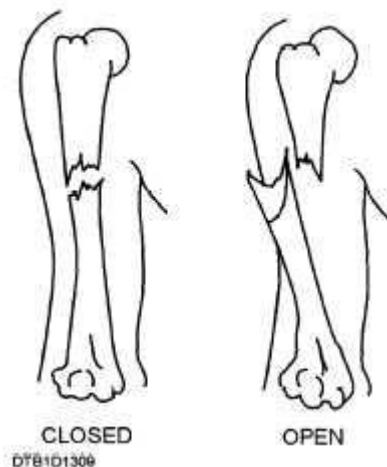
The first step in describing a fracture is whether it is an **open or closed** fracture.

What Is an Open Fracture?

An open fracture (also called a compound fracture) is a fracture where a piece of the broken bone pierces through the skin. This can be dangerous because the bone is exposed, increasing the risk of infection.

What Is a Closed Fracture?

A closed fracture, (the most common type) is a fracture where the bone is broken, but does not come through the skin. Some bad closed fractures are deformed, but the bone has not broken the skin, this is still considered a closed fracture if the bone is has not broken the skin.



Symptoms

The most common symptoms (but not all inclusive) of a fracture are:

- Swelling around the injured area
- Loss of function in the injured area
- Pain
- Bruising around the injured area (but not always)
- Deformity of a limb (but not always)

Diagnosis

What tests will my doctor run?

Diagnosis is made by history, physical exam, and tests like x-ray. Nevertheless, depending on the type of fracture, sometimes an x-ray is all that is needed to diagnosis a fracture. However, if your doctor thinks there is a fracture, but it is unclear on the x-ray your doctor can order other tests to be done to diagnosis if there is a fracture or not. Other possible test included: a bone scan, CT scan, or MRI or MRI Arthrogram may be done to confirm the diagnosis.

[Related Document: A Patient's Guide to Bone scans](#)

[Related Document: A Patient's Guide to CT scans](#)

[Related Document: A Patient's Guide to MRI](#)

[Related Document: A Patient's Guide to MRI Arthrogram](#)

Types of fractures

There are many types of fractures: simple, stress, comminuted, impacted, compound, complete and incomplete. To find your type of fracture see what page it is located on or read about all the types of fractures.

There are two main types of fractures:

- Incomplete: Bone cracks but doesn't separate – example of fractures: greenstick and hairline.
- Complete: Bone snaps completely into two or more pieces – fractures that break all the way through.

Types of fractures, x-rays, photos, and information are found on the following pages:

Video link of the following different kinds of fractures can be found on page 4

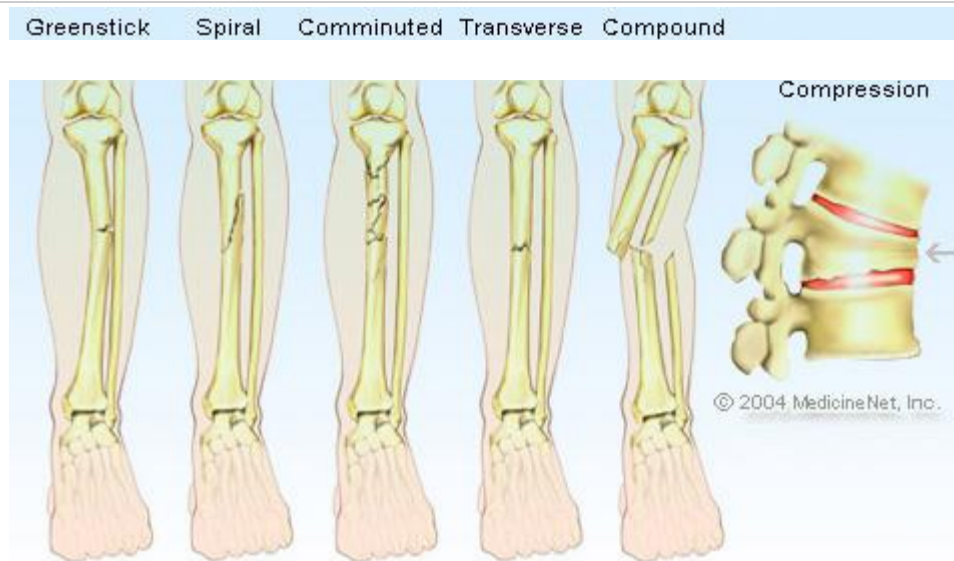
- Incomplete fracture:.....Page 5
- Hairline fracture:.....Page 6
- Greenstick fracture:.....Page 7
- Complete Fracture:.....Page 8
- Simple fracture:.....Page 9
- Comminuted (or multifragmentary) fracture:....Page 10
- Stress fracture:.....Page 11
- Compression fracture:.....Page 12
- Avulsion fracture:.....Page 13
- Impacted fracture:.....Page 14
- Pathologic fracture:.....Page 15

Videos of different kinds of fractures:

Copyrighted animations provided by Blausen Medical.

Video 1: <http://video.about.com/orthopedics/Fractures-1.htm>


Video 2: <http://video.about.com/orthopedics/Fractures-2.htm>



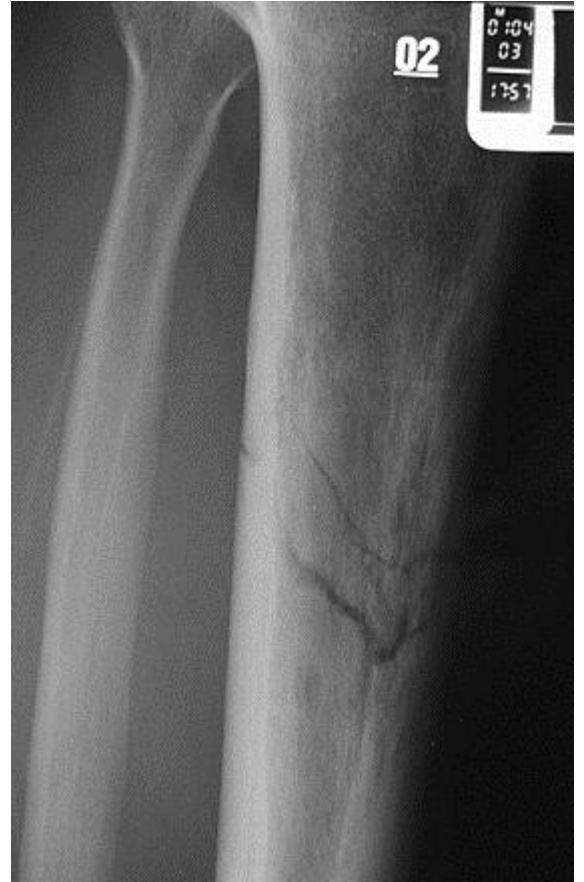More detailed discussion of the Types of Fractures:

What Is an Incomplete Fracture?

When the bone is only cracked or partially broken, doctors refer to it as an incomplete fracture. An example of an incomplete fracture is a Greenstick and often a Hairline fracture.

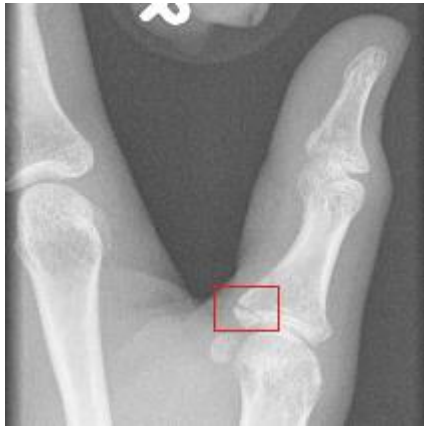

← Incomplete fracture →

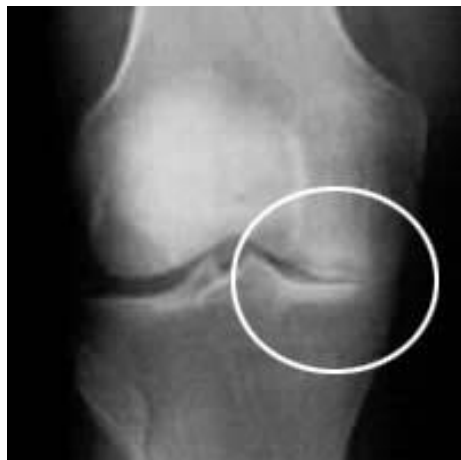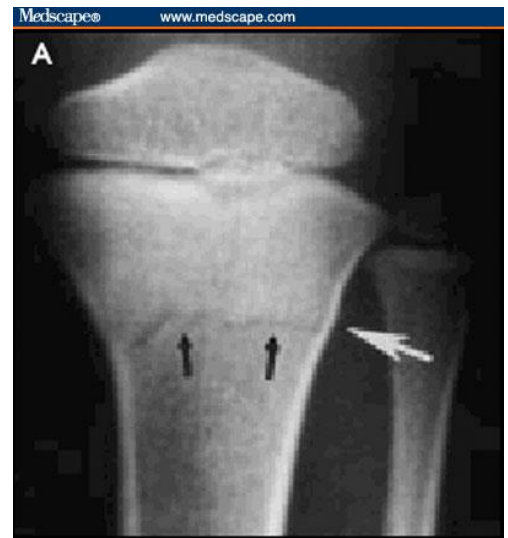


What Is a Hairline Fracture?

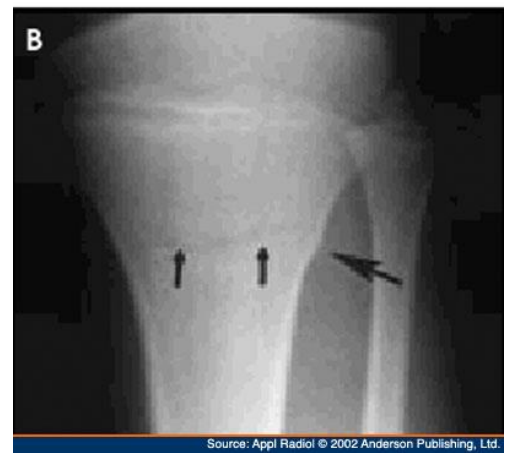A hairline fracture is often an incomplete fracture, like a crack that does not break all the way through the bone. It usually is the result of a relatively minor injury.



←Hairline fracture→



← Hairline fracture →



What Is a Greenstick Fracture?

A greenstick fracture is an incomplete fracture that is similar to the break of a young tree branch. Only one side of the bone breaks causing the bone to bend.

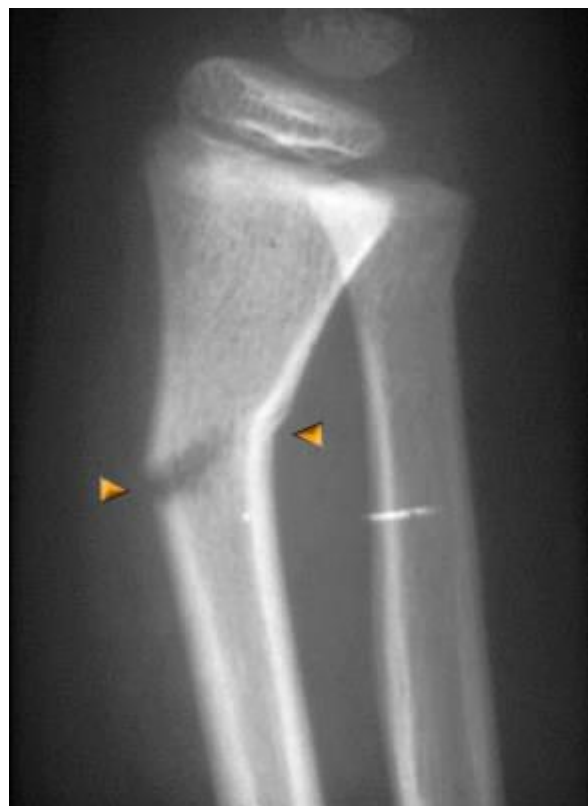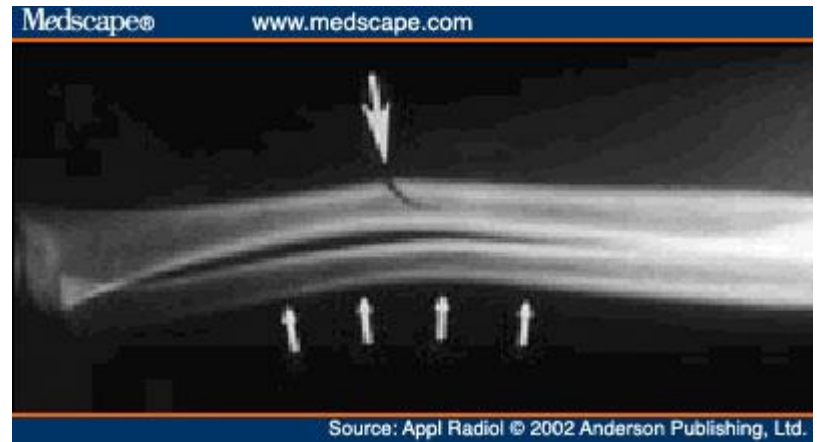Both hairline and greenstick fractures are usually treated by immobilization with a cast to allow it to mend.



Greenstick fracture →


← Greenstick

Greenstick fracture →



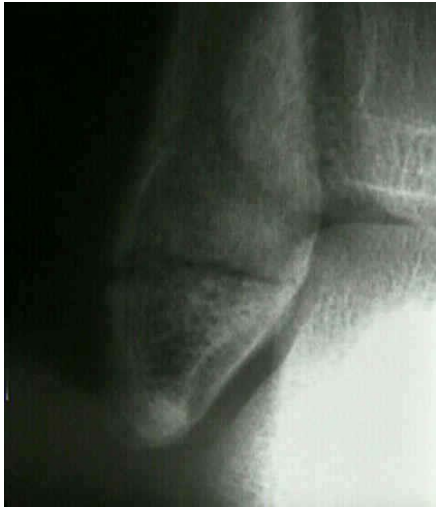What Is a Complete Fracture?

When the bone is broken into two or more pieces, doctors refer to it as a complete fracture. These are all other fractures that are Not Greenstick or (most) Hairline fractures; remember Greenstick or Hairline fractures to do not go all the way through the bone (also known as: incomplete fractures). If the break goes all the way through the bone is broken in two or more pieces it is a complete fracture.


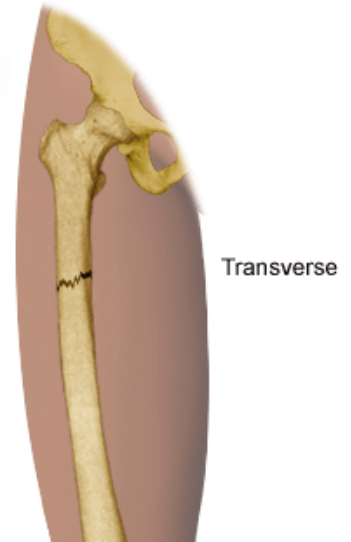


What Is a Simple Fracture?

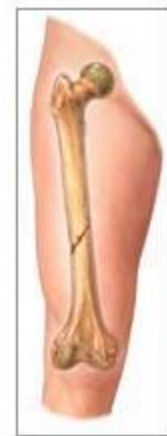A simple fracture is a complete fracture where the bone is broken into two fragments. This break can be transverse (which means straight across the bone), oblique (which means at an angle)....and spiral (which means an angle that is twisted).




← Simple Transverse fracture →



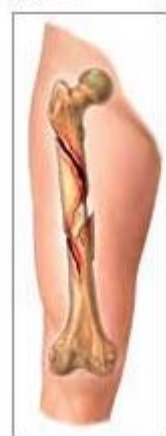← Simple Oblique fracture →



Oblique



← Simple Spiral fracture →

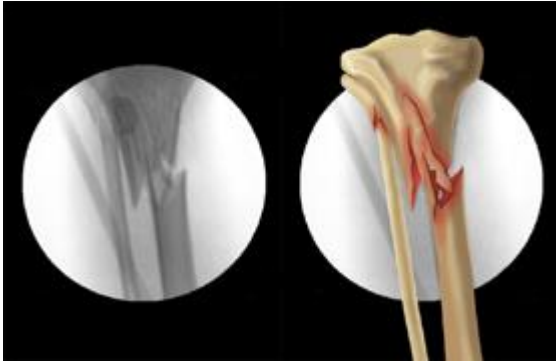


Spiral

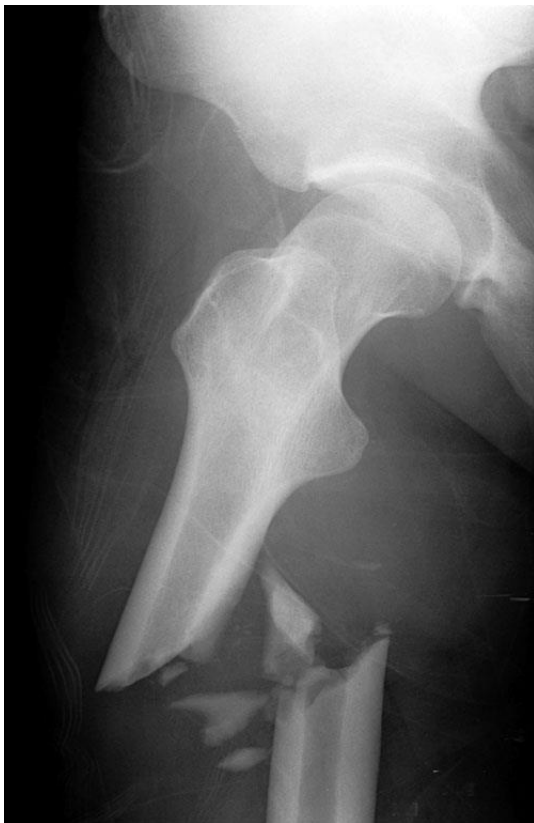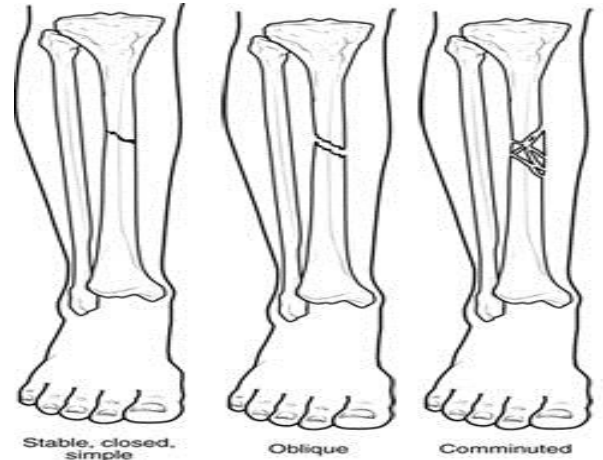
What is a Comminuted Fracture?

A comminuted (or multifragmentary) fracture is a complete fracture where the bone is broken into several fragments. This type of fracture is usually a result of a severe injury.

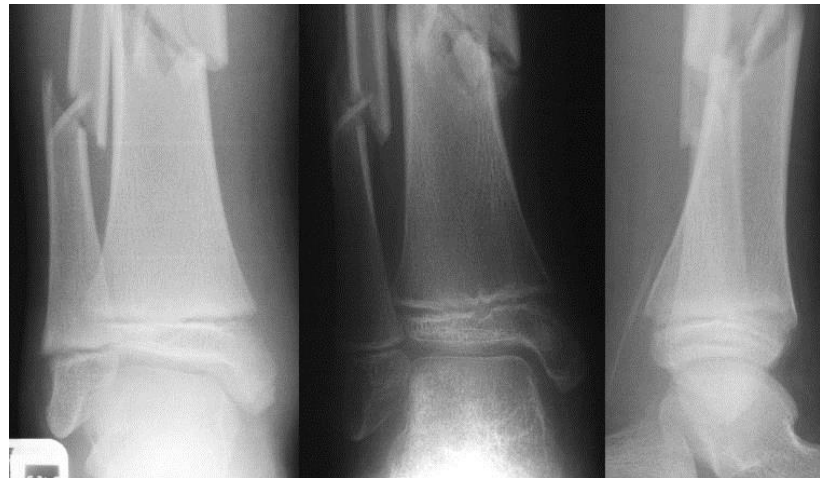Both simple and comminuted fractures are usually treated with immobilization with a cast or sometimes with pins, screws, and plates.



← Comminuted fracture



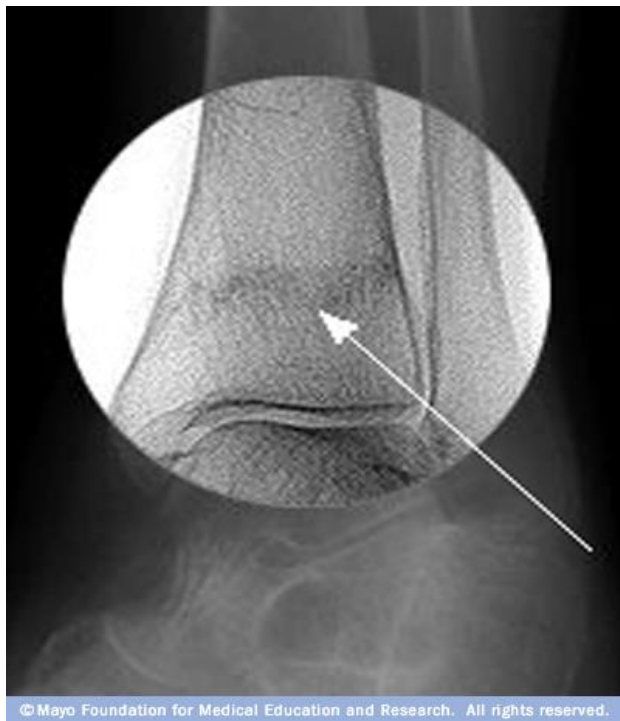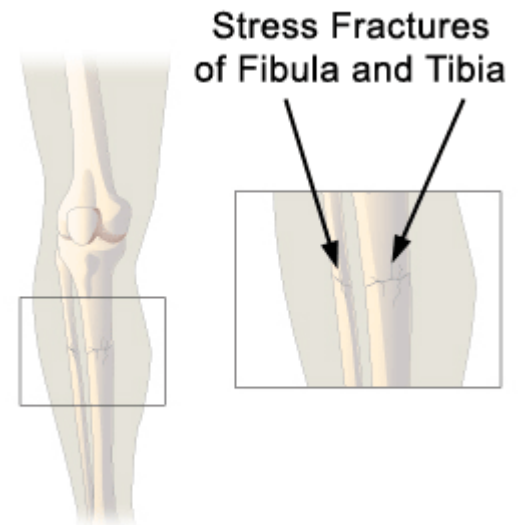
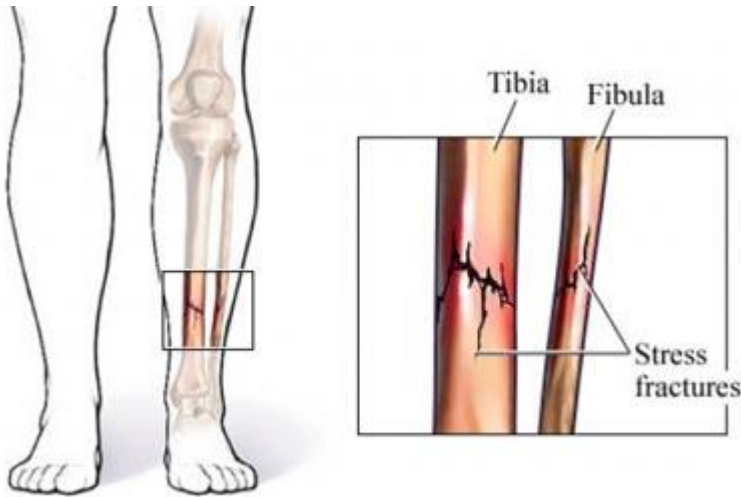
Comminuted Fracture →



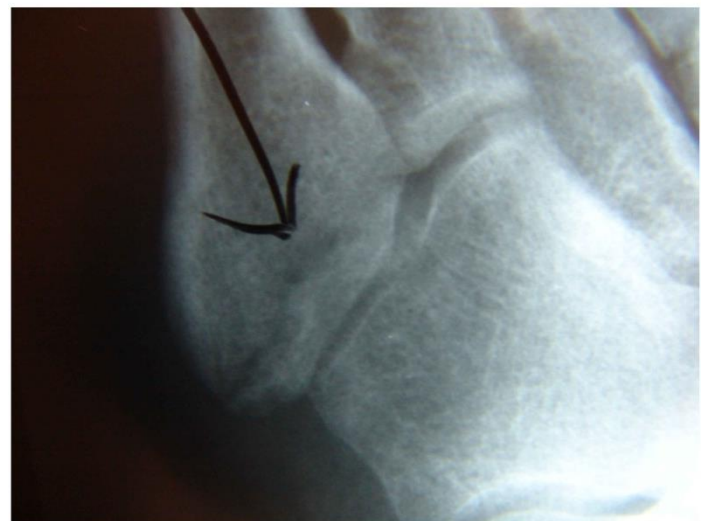← Comminuted fracture

What is a Stress Fracture?

A stress fracture is an overuse (chronic) injury as a result from many repeated small stresses on a bone. Because of repeated micro-trauma “Microscopic fractures” form, the bone fails to absorb all the shock that is being put upon it and become weakened and if not given time to heal, can join to form a stress fracture. This fracture is most often seen in the lower leg, the shin bone (tibia), or foot. Athletes who perform repetitive vigorous activities are at risk the most, because they have repeated footfalls on hard surfaces. Examples of these athletes are: Tennis players, basketball players, jumpers, and gymnasts are typically at risk for this type of fracture.



Stress fracture →



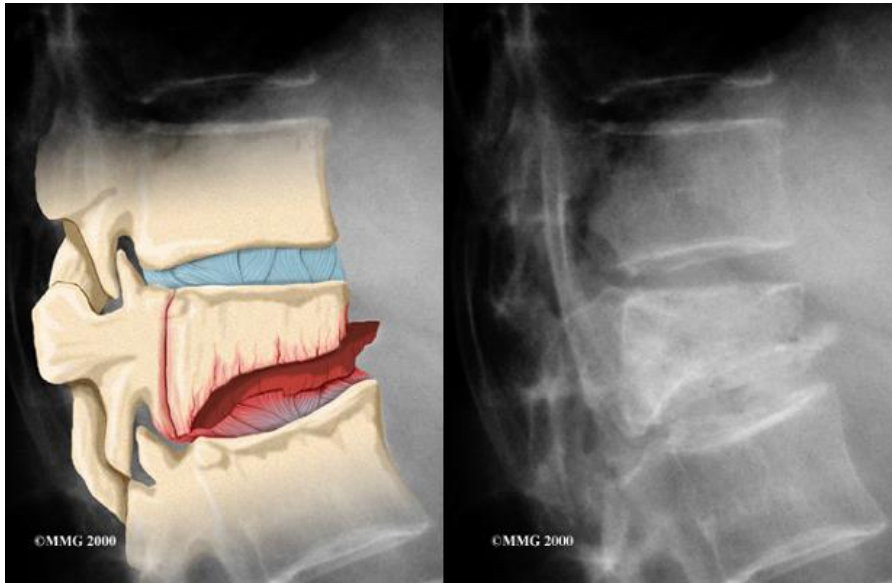
← Stress fracture

Shin splints may develop and become a stress fracture; if no fracture shin splints can have very similar symptoms as a stress fracture of the tibia but they are due to inflammation of the lining of the bone, called the periosteum. Shin splints are caused by overuse, especially in runners, walkers, dancers, including those who do aerobics. Muscles that run through the periosteum and the bone itself may also become inflamed.

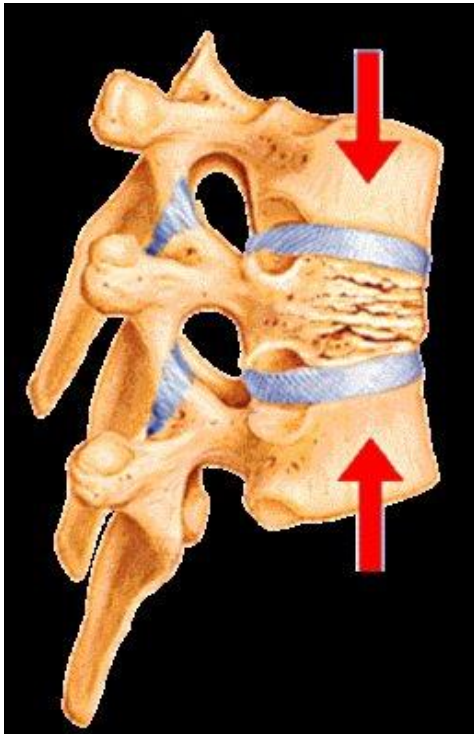
[Related Document: A Patient's Guide to Shin splints](#)

What Is a Compression Fracture?

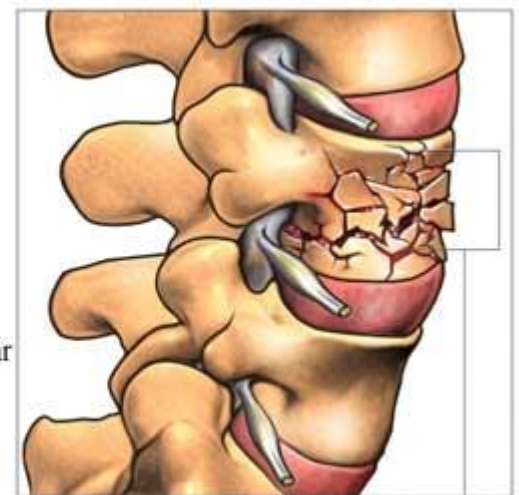
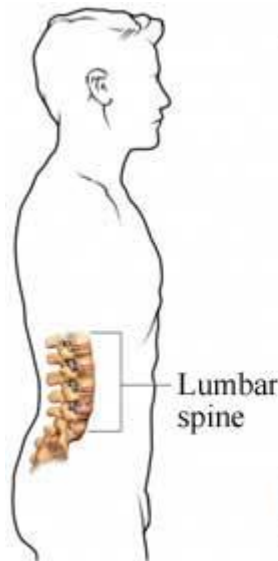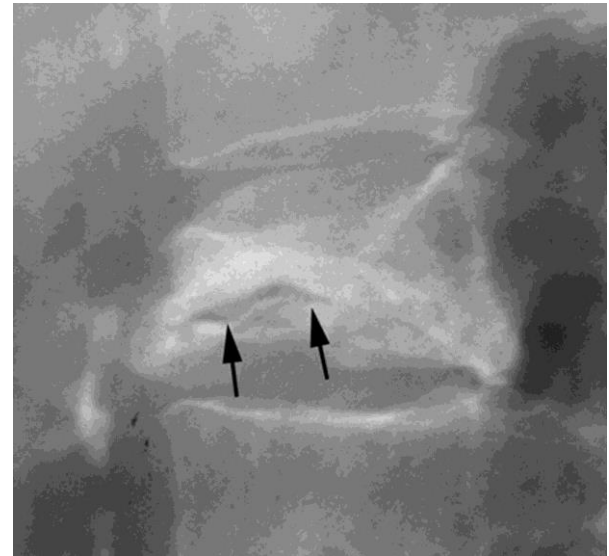
A compression fracture is a closed fracture that occurs when two or more bones are forced against each other. It commonly occurs to bones of the spine and may be caused by falling into a standing or sitting position, or a result of advanced osteoporosis.



← Compression fracture



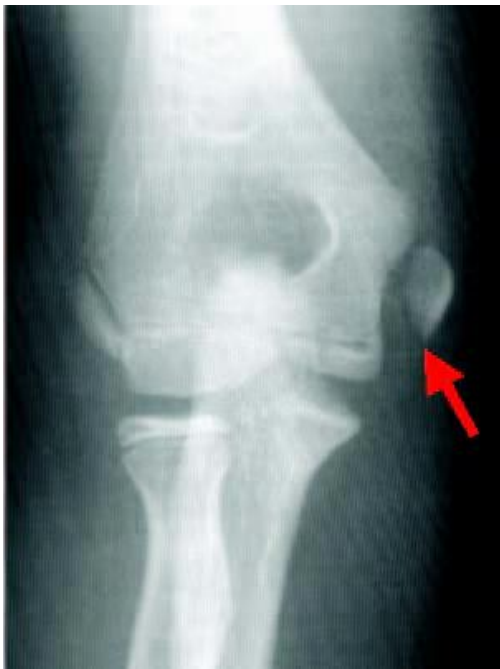Compression fracture →



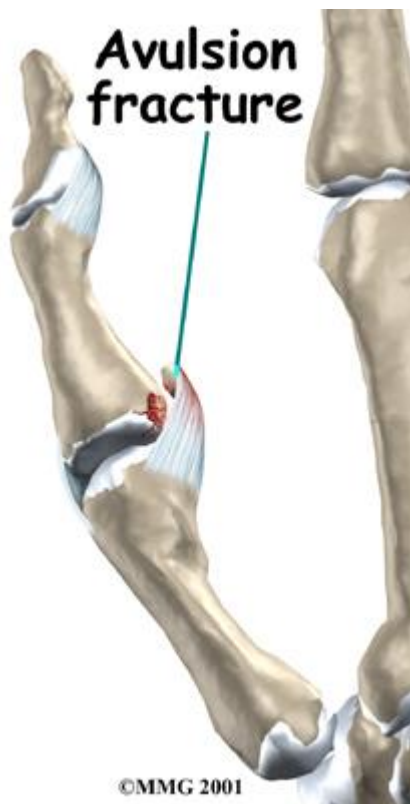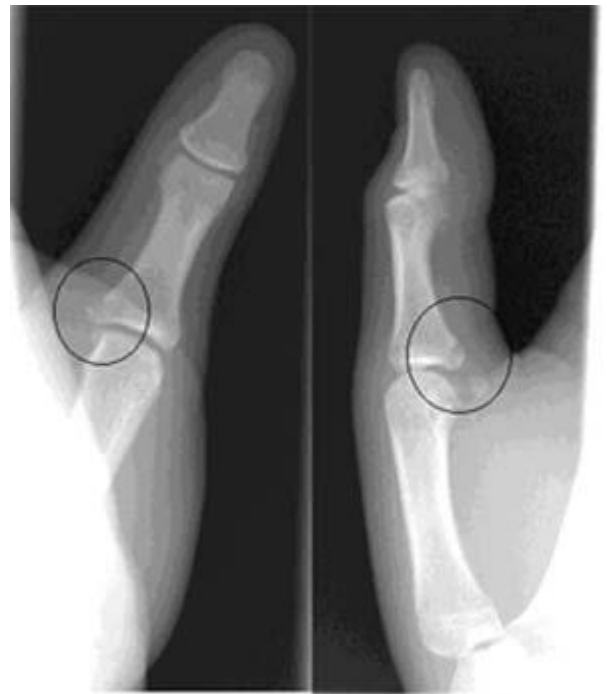Compression fracture

What Is an Avulsion Fracture?

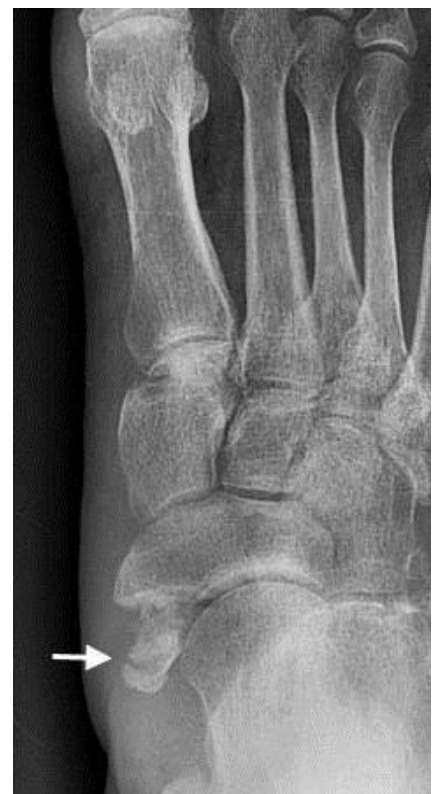An avulsion fracture is a closed fracture where a piece of bone is broken off by a sudden, forceful contraction of a muscle. This type of fracture is common in young athletes and can occur when muscles are not properly stretched before activity. This fracture can also be the result of an injury.



← Avulsion fracture →

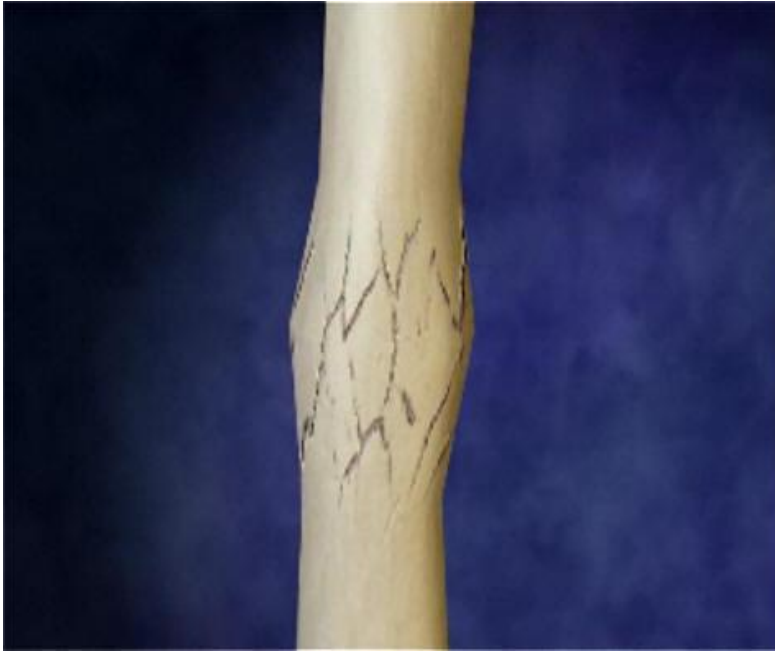

Avulsion fracture →

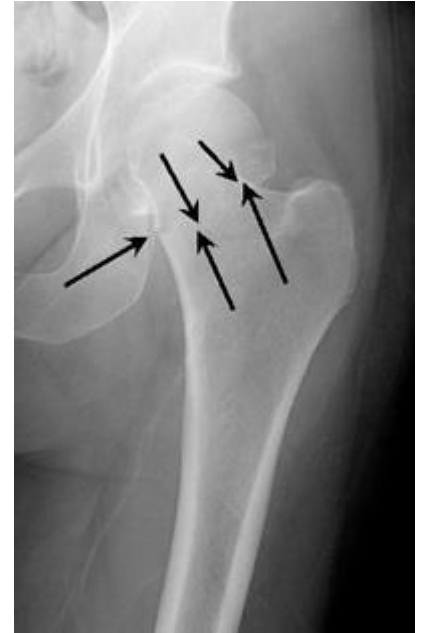

What Is an Impacted Fracture

An impacted fracture is similar to a compression fracture, yet it occurs within the same bone. It is a closed fracture that occurs when pressure is applied to both ends of the bone, causing it to split into two fragments that jam into each other. This type of fracture is common in falls and car accidents.

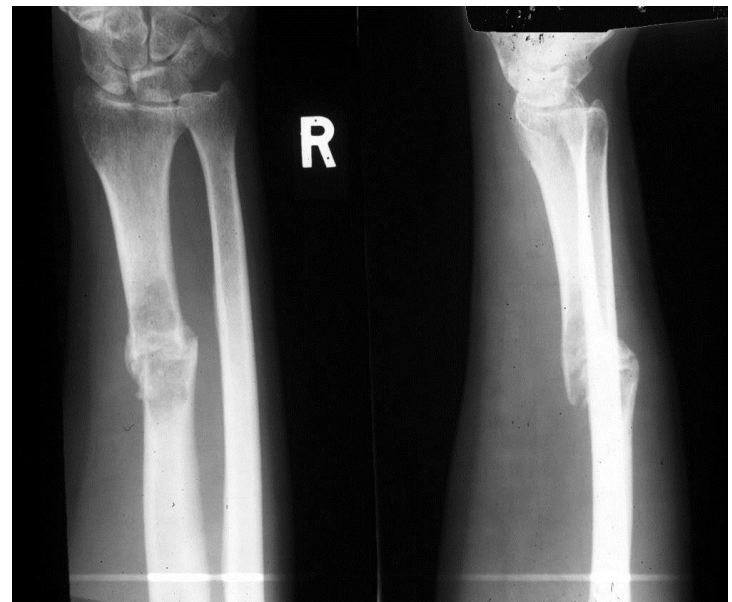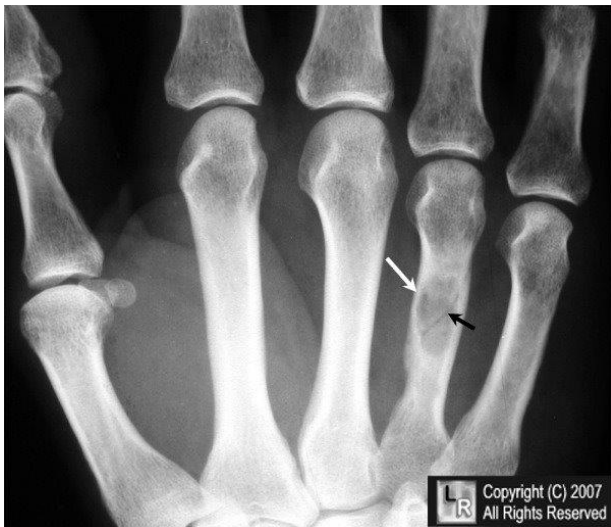

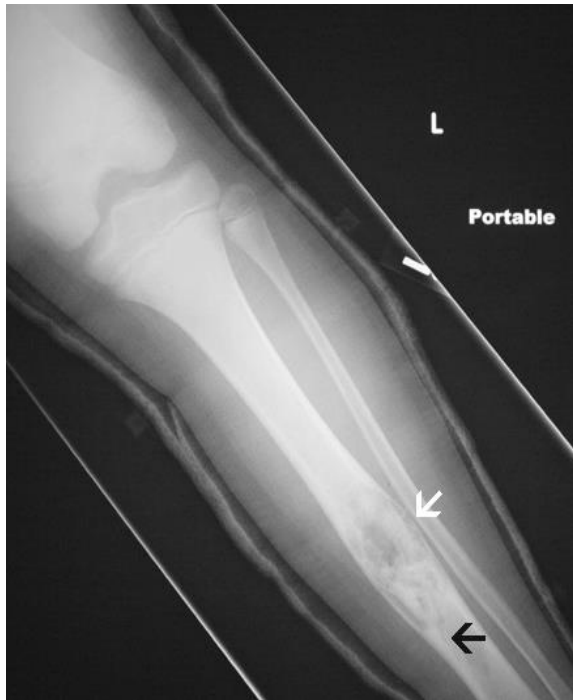

← Impacted
fracture →



What is a pathologic Fracture?

A pathologic fracture happens with minimal or no injury to an abnormal bone. This is usually caused by an underlying weakness or problem with the bone itself, such as osteoporosis or tumor.



Treatment

What treatment options are available?

Nonsurgical Treatment

The treatment of a specific fracture is too complicated to be discussed in a general overview of broken bones, but depends on factors such as:

- Location of the fracture
- Severity of angulation or deformity
- Potential for healing
- Other injuries
- Age and activity level of the patient
- And many more factors....

In order to understand your treatment, and the options you may have for treatment, you need to discuss your fracture with your doctor. Because treatments are individualized based on the patient, the x-ray appearance of the fracture, and the other factors mentioned, each case must be treated individually.

When the ends of the bone are aligned, the injured bone requires support and protection while it heals. A cast or splint usually provides this support and protection. Many factors affect the rate at which a fracture heals and the amount of time a person needs to wear a cast. Ask a doctor how much time the specific fracture will take to heal.

If the doctor puts you in a cast/splint while healing, please see the patient's guide on how to take care of the cast.

[Related Document: A Patient's Guide to How to Anterior Taking Care for Your New Cast](#)

Possible Surgical Treatment

Reduction/Reducing of a fracture bone

When doctors talk about *reduction* or a fracture, or *reducing* the broken bone, they are talking about improving the alignment of the broken ends of the bone. When a bone is fractured and out of place (or not lined up like it was), it may require a reduction or realignment to put the ends of the fracture back into place (or lined back up). After you are given medication for pain a qualified doctor will do this by moving the fractured bone into alignment with his or her hands or using special medical equipment. If a bone has a fracture but is not out of position or deformed, no reduction is necessary.

In most cases reducing a fracture involves placing the broken bone in a cast, often after a little pulling and tugging to achieve improved alignment. If the reduction cannot be satisfactorily achieved (meaning the alignment is either not adequate or not sufficiently stable), then a further procedure may be necessary. This usually means surgery with fixation of the bone with pins, plates, screws or rods.

Treatment continue...

Mal-union/non-union of a fracture bone

A nonunion occurs when a broken bone does not heal. Bones have a tremendous capacity for healing themselves, and with proper treatment, most all fractures will heal without complication. However, some fractured bones have difficulty healing. When a bone is slow to heal, we call this a "*delayed union*." When a bone does not heal, we call this a "*nonunion*."

What is the cause of a nonunion?

Determining the cause of a nonunion is critical to determining the proper treatment. The most common causes of nonunion are:

- Infection
- Inadequate blood flow to the bone
- Separation of the fractured ends of the bone
- Inadequate stabilization of the fracture

What bones are most commonly involved in nonunion?

Any broken bone can develop into a nonunion, but several bones are notorious for nonunion development. The reason is that the blood flow to these bones is poor, and therefore, they are a 'set-up' for a nonunion. The most common fractured bone that is most known to become a nonunion is the Navicular (Scaphoid) bone of the wrist partly because of its poor blood, or not knowing the wrist injury was a fracture vs. a wrist sprain. Nonunion bones often need surgery to be fixed.

[Related Document: A Patient's Guide to Navicular \(Scaphoid\) Fracture of the Wrist](#)

Surgery

Surgery on fractures are very much dependent on what bone is broken, where it is broken, and whether the orthopedic surgeon believes that the break is at risk (for staying where it is) once the bone fragments have been aligned. If the surgeon is concerned that the bones will heal improperly, an operation will be needed. Sometimes bones that appear to be aligned normally are splinted, and at a recheck appointment, are found to be unstable and require surgery.

Surgery can include *closed reduction* and casting, where under anesthesia, the bones are manipulated so that alignment is restored and a cast is placed to hold the bones in that alignment. Sometimes, the bones are broken in such a way that they need to have metal hardware inserted to hold them in place. *Open reduction* means that, in the operating room, the skin is cut open and pins, plates, or rods are inserted into the bone to hold it in place until healing occurs. Depending on the fracture, some of these pieces of metal are permanent (never removed), and some are temporary until the healing of the bone is complete and surgically removed at a later time.

How long your injury will take to heal after surgery all depends on many factors, talk with your doctor about your questions on how long recovery will take.

Rehabilitation / Recovery

What should I expect after treatment?

Nonsurgical Rehabilitation

How long and what kind of rehabilitation you will go through after your injury all depends on many factors, talk with your doctor about your questions about recovery and what kind of rehabilitation you will go through.

Rehabilitation/Recovery After Surgery

How long and what kind of rehabilitation you will go through after your injury all depends on many factors, talk with your doctor about your questions about recovery and what kind of rehabilitation you will go through.

* References available upon request